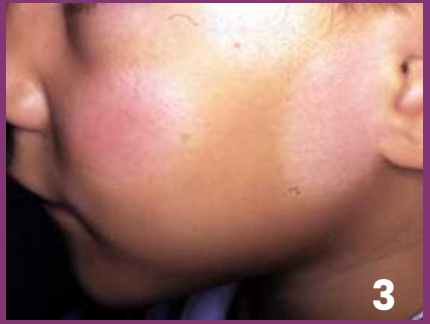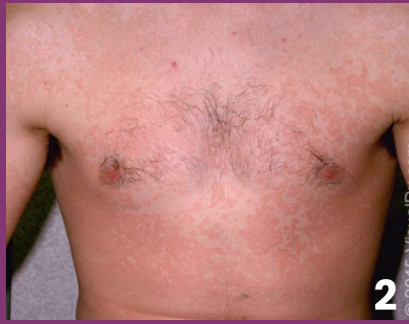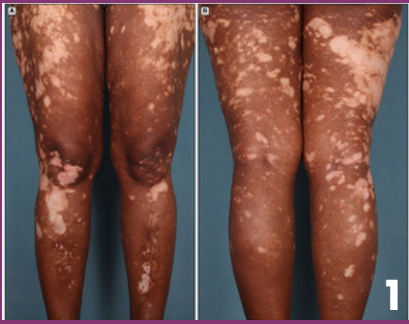


# Common Depigmented and Hypopigmented Rashes



Disease

Vitiligo

Pityriasis  
(Tinea)  
Versicolor

Pityriasis Alba

Presentation

Asymptomatic depigmented macules and patches that are milk or chalk-white in colour and lack clinical signs of inflammation.

Macules, patches and thin plaques that can appear hypopigmented, hyperpigmented or mildly erythematous.

Numerous patches or thin plaques with poorly defined edges and associated fine scales with hypopigmentation.

Location

Predilection for the face, around the orifices, genitals and hands but can appear anywhere on the body.

Most common around the trunk, neck, and/or arms due to the increased sebum production, creating a more optimal nutritional requirement for the yeast.

Most commonly occurs on the face. Can also appear on the neck, shoulders and upper arms.

Comorbidities

Depigmented hairs  
Halo nevi  
Premature graying  
Highly associated with comorbid autoimmune diseases if onset as a teen or adult.

Mild pruritus  
May coexist with seborrheic dermatitis.

May be associated with atopic dermatitis, however, pityriasis alba can present in non-atopic individuals as well.


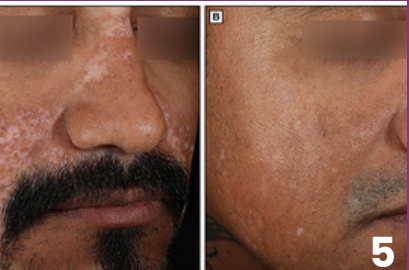




Population

Average 20-24, with bimodal onset of <10 years or around 30 years but can occur at any age.

More common in males than females. More common in hot and humid climates. More common in individuals who perspire heavily.

Most common in children and adolescents. Rarely seen in adults.

# ... Continued

Disease	Vitiligo	Pityriasis (Tinea) Versicolor	Pityriasis Alba
Causes	Auto-immune destruction of melanocytes where tyrosinase is a principal auto-antigen of autoimmune vitiligo	It is caused by mycelial growth of Malassezia fungi. Malassezia flourishes through the degradation of fatty acids.	The exact cause is not known. Pityriasis alba often co-exists with dry skin and atopic dermatitis.
Treatments	<p><b>Mild:</b> topical corticosteroids, topical calcineurin inhibitors, topical ruxolitinib</p> <p><b>Moderate-Severe:</b> targeted phototherapy, systemic immunosuppressants, PUVA photochemotherapy,, grafting procedures.</p>	<p><b>Mild:</b> Selenium sulphide shampoo, Topical -azole cream/shampoo, Terbinafine gel</p> <p><b>Moderate:</b> Oral -azole antifungals</p> <p>Note that terbinafine is not effective for yeast infections such as pityriasis versicolor.</p>	<p>No specific treatment is necessary, most cases resolve within a few months to a year.</p> <p>General measures include: moisturizers, mild topical corticosteroids.</p> <p>If redness and itch are present, calcineurin inhibitors can be used in areas where topical steroids want to be avoided.</p>
Additional Images	 <p>4</p>  <p>5</p>	 <p>6</p>  <p>6</p>	 <p>7</p>  <p>8</p>

## References

1. Grimes P. Vitiligo: Pathogenesis, clinical features, and diagnosis - UpToDate. UpToDate. Accessed August 9, 2023. [https://www-uptodate-com.myaccess.library.utoronto.ca/contents/vitiligo-pathogenesis-clinical-features-and-diagnosis?search=hypopigmentation&topicRef=103736&source=see\\_link#H79502398](https://www-uptodate-com.myaccess.library.utoronto.ca/contents/vitiligo-pathogenesis-clinical-features-and-diagnosis?search=hypopigmentation&topicRef=103736&source=see_link#H79502398)
2. Alsayaydeh B. Vitiligo. DermNet. <https://dermnetnz.org/topics/vitiligo>
3. Goldstein B, Goldstein A. Tinea versicolor (pityriasis versicolor) - UpToDate. UpToDate. Accessed August 9, 2023. [https://www-uptodate-com.myaccess.library.utoronto.ca/contents/tinea-versicolor-pityriasis-versicolor?search=hypopigmentation&source=search\\_result&selectedTitle=2~150&usage\\_type=default&display\\_rank=2](https://www-uptodate-com.myaccess.library.utoronto.ca/contents/tinea-versicolor-pityriasis-versicolor?search=hypopigmentation&source=search_result&selectedTitle=2~150&usage_type=default&display_rank=2)
4. Oakley A. Pityriasis alba. DermNet. <https://dermnetnz.org/topics/pityriasis-alba>
5. Oakley A. Pityriasis versicolor. DermNet. <https://dermnetnz.org/topics/pityriasis-versicolor>
6. Roh MR, Oh SO. Acquired hypopigmentation disorders other than vitiligo - UpToDate. UpToDate. Accessed August 9, 2023. [https://www-uptodate-com.myaccess.library.utoronto.ca/contents/acquired-hypopigmentation-disorders-other-than-vitiligo?search=pityriasis%20alba&sectionRank=1&usage\\_type=default&anchor=H2110840350&source=machineLearning&selectedTitle=1~8&display\\_rank=1#H2110840350](https://www-uptodate-com.myaccess.library.utoronto.ca/contents/acquired-hypopigmentation-disorders-other-than-vitiligo?search=pityriasis%20alba&sectionRank=1&usage_type=default&anchor=H2110840350&source=machineLearning&selectedTitle=1~8&display_rank=1#H2110840350)
7. Picardo M, Dell'Anna ML, Ezzedine K, et al. Vitiligo. *Nat Rev Dis Primer*. 2015;1(1):15011. doi:10.1038/nrdp.2015.11
8. Song, Y. H., Connor, E., Li, Y., Zorovich, B., Balducci, P., & Maclaren, N. (1994). The role of tyrosinase in autoimmune vitiligo. *Lancet* (London, England), 344(8929), 1049–1052. [https://doi.org/10.1016/s0140-6736\(94\)91709-4](https://doi.org/10.1016/s0140-6736(94)91709-4)
9. Lyubomir A Dourmishev, M. (2023, June 14). Pediatric tinea versicolor workup. Laboratory Studies, Imaging Studies, Other Tests. <https://emedicine.medscape.com/article/911138-workup>

## Image Citations

Vitiligo Images: [https://www-uptodate-com.myaccess.library.utoronto.ca/contents/vitiligo-pathogenesis-clinical-features-and-diagnosis?search=hypopigmentation&topicRef=103736&source=see\\_link#H79502398](https://www-uptodate-com.myaccess.library.utoronto.ca/contents/vitiligo-pathogenesis-clinical-features-and-diagnosis?search=hypopigmentation&topicRef=103736&source=see_link#H79502398)

Pityriasis (Tinea) Versicolour Images: [https://www-uptodate-com.myaccess.library.utoronto.ca/contents/tinea-versicolor-pityriasis-versicolor?search=hypopigmentation&source=search\\_result&selectedTitle=2~150&usage\\_type=default&display\\_rank=2#H4](https://www-uptodate-com.myaccess.library.utoronto.ca/contents/tinea-versicolor-pityriasis-versicolor?search=hypopigmentation&source=search_result&selectedTitle=2~150&usage_type=default&display_rank=2#H4)

Pityriasis Alba Images: <https://dermnetnz.org/topics/pityriasis-alba>