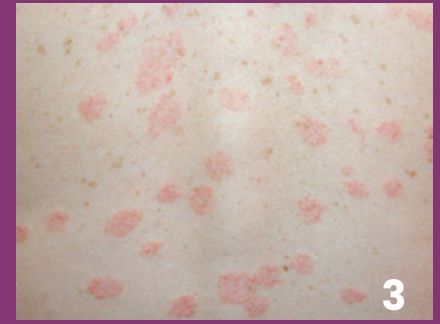
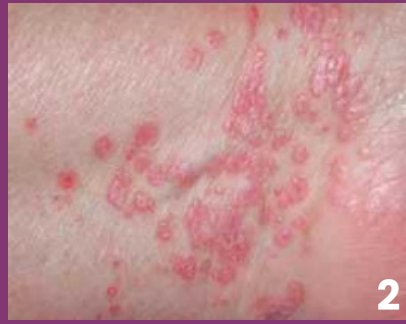
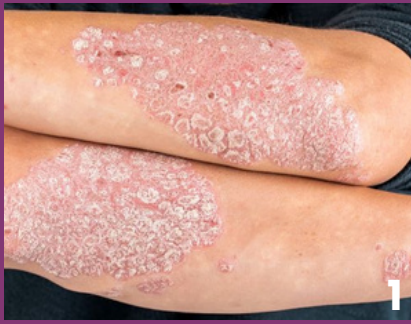Papulosquamous Diseases



Disease

Plaque Psoriasis

Lichen Planus

Pityriasis Rosea

Presentation

Well-demarcated red plaques with silvery-scale

Purple, shiny, pruritic, polygonal papules with a flat top.

Described with 6 "P"s: plantar, purple, polygonal, pruritic, papules, and plaques

Onset with a large circular "herald patch" to the chest, abdomen or back.

Two weeks later, scaly salmon-pink plaques present in a "Christmans tree" on the chest or back

Location

Extensor surfaces of elbows, knees, neck, scalp, and trunk;
Also associated with nail changes

Scalp, extremities, genitals, and mucous membranes.
More common within flexural surfaces

Oral Lichen Planus:
Most commonly with painless white streaks in a fern-like or lacy pattern called "Wickham Striae"

Papules appear in parallel lines to skin stress, commonly on the abdomen or back

Comorbidities

Associated with psoriatic arthritis, obesity, diabetes, metabolic syndrome, Crohn's disease, and mood disorders

Associated with HCV infection, alopecia areata, and ulcerative colitis

Associated with prodromal symptoms of malaise, nausea, headache, and upper respiratory symptoms



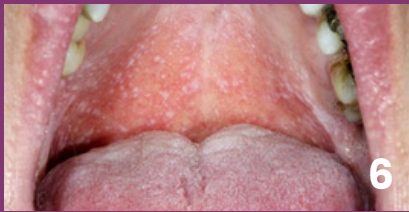



Onset

Bi-modal peak of onset: 20-30 and 50-60 years of age

Can appear at any age, most common between 30-60 years of age

Most common in children and young adults

Papulosquamous Diseases Continued

Disease	Plaque Psoriasis	Lichen Planus	Pityriasis Rosea
Causes	Chronic immune-mediated excess keratinization and angiogenesis in the skin	Idiopathic inflammatory condition	Acute, self-limiting inflammatory condition triggered by viral infection (HHV6/7)
Treatments	<p>Mild: Trigger avoidance, emollients, medium potency topical corticosteroids alone or in combination with other agents, such as Vitamin D derivatives, tazarotene, coal tar, calcineurin inhibitors</p> <p>Moderate: High potency topical corticosteroids, phototherapy</p> <p>Severe: Systemic treatments with acitretin, immunosuppressants (cyclosporine, methotrexate), or biologics (TNF-alpha, IL-17, IL-23 inhibitors)</p>	<p>First Line: High potency corticosteroids</p> <p>Adjunct: Topical calcineurin inhibitors and intralesional steroids injections as an adjunct if needed</p> <p>Severe: Systemic corticosteroids or acitretin</p>	<p>Symptomatic treatment only for majority of cases</p> <p>Severe: Acyclovir can be useful for persistent or relapsing cases</p>
Additional Images	 4  5	 6  7	 8  9

References

1. Arelis Burgos-Zavoda, Joanna M. Burch, Papulosquamous disorders, Editor(s): Lalit Bajaj, Simon J. Hambidge, Gwendolyn Kerby, Ann-Christine Nyquist, Berman's Pediatric Decision Making (Fifth Edition), Mosby, 2011, Pages 114-115
2. Armstrong AW, Read C. Pathophysiology, Clinical Presentation, and Treatment of Psoriasis: A Review. JAMA. 2020 May 19;323(19):1945-1960. doi: 10.1001/jama.2020.4006. PMID: 32427307.
3. Usatine RP, Tinitigan M. Diagnosis and treatment of lichen planus. Am Fam Physician. 2011 Jul 1;84(1):53-60. PMID: 21766756.
4. Le Cleach L, Chosidow O. Clinical practice. Lichen planus. N Engl J Med. 2012 Feb 23;366(8):723-32. doi: 10.1056/NEJMcp1103641. PMID: 22356325.
5. Boch K, Langan EA, Kridin K, Zillikens D, Ludwig RJ, Bieber K. Lichen Planus. Front Med (Lausanne). 2021 Nov 1;8:737813. doi: 10.3389/fmed.2021.737813. PMID: 34790675; PMCID: PMC8591129.
6. Drago F, Ciccarese G, Rebora A, Broccolo F, Parodi A. Pityriasis Rosea: A Comprehensive Classification. Dermatology. 2016;232(4):431-7. doi: 10.1159/000445375. Epub 2016 Apr 21. PMID: 27096928.

Image Citations

1. Psoriasis Image 1: <https://www.usdermatologypartners.com/blog/what-is-plaque-psoriasis/>
2. Lichen Planus Image 1: <https://dermnetnz.org/topics/lichen-planus>
3. Pityriasis Rosea Image 1: <https://mydermcenter.com/pityriasis-rosea/>
4. Psoriasis Image 2: <https://www.healthline.com/health/psoriasis>
5. Psoriasis Image 3: <https://www.healthline.com/health/psoriasis-on-black-skin>
6. Lichen Planus Image 2: <https://www.gponline.com/oral-lichen-planus/article/946511>
7. Lichen Planus Image 3: <https://www.dermatologyadvisor.com/home/decision-support-in-medicine/dermatology/lichen-planus/>
8. Pityriasis Rosea Image 2: <https://www.merckmanuals.com/en-ca/professional/multimedia/image/pityriasis-rosea-back>
9. Pityriasis Rosea Image 3: <https://www.nhs.uk/conditions/pityriasis-rosea/>